

Endodontic Therapy of a Mandibular First Molar With a Middle Mesial Canal

Rajiv Patel BDS, DDS*

Root canal anatomy and configuration have continued to demonstrate dynamic variations from individual to individual and within the same individual. The knowledge of and attention to typical and atypical anatomy can be a critical factor in determining the success of endodontic therapy. The utilization of proper magnification, adequate illumination, and knowledge of morphological variations can ensure predictability of the treatment rendered.

The roots and canals of mandibular permanent first molars have several typical anatomical features, as well as a great number of anomalies. Recent literature suggests that there is a 1% to 15% chance of a fifth canal in a mandibular first molar.¹ Among the most frequent types of teeth treated by root canal therapy, mandibular first molars are the most prominent statistically in comparison to other types of teeth.^{2,3}

CASE PRESENTATION

A 44-year-old Hispanic male patient presented to the dental office with a history of spontaneous pain for five days. The patient complained of sensitivity when chewing hot and cold food, especially ice, and pain when biting on the left side. The patient's medical history was noncontributory and the patient was not taking any medications. On clinical examination, a fractured distal marginal ridge with recurrent caries under a portion of occlusal amalgam on tooth #19(36) was observed (Figure 1). The tooth was very sensitive to percussion and showed a lingering pain response to cold application. Apical palpation was normal. Radiographs revealed a deep, carious lesion with close proximity to the pulp and no significant periapical changes. A diagnosis of irreversible pulpitis with acute apical periodontitis was made.

Emergency treatment for the patient comprised of instrumentation of two mesial canals and two confluent distal canals. The tooth also had a mesial crack line extending from the mesial marginal ridge and disappearing into the roof of the mesial side of the pulpal floor. The probing depths were within normal limits. The tooth was temporarily sealed with a cotton pellet and an interim restorative material due to the limitation of time with respect to completion of procedure at the same visit. An intracanal medication was not placed since the patient was scheduled the subsequent day for completion of the root canal procedure.

On the second visit, the isthmus between the orifices of the mesial canals appeared conspicuous due to the continued bubbling effect of sodium hypochlorite irrigation solution (Figure 2). Careful troughing with a surgical length carbide straight fissure bur and patient exploration with small hand files led to the discovery of a middle mesial canal (Figures 3 and 4). A wire film radiograph confirmed the presence of the middle mesial canal.

In this case, the confluent middle mesial canal joined the mesiobuccal canal at the apical third; the mesiolingual canal remained separate (Figures 5 and 6). The two distal canals joined to exit in a single foramen. The canals were instrumented with hand and nickel-titanium rotary endodontic instruments (eg, ProTaper, Dentsply Tulsa Dental, Tulsa, OK; K3, Sybron Endo, Orange, CA). Alternating irrigations of 5.25% sodium hypochlorite and 17% ethylenediamine tetraacetic acid (EDTA) were used, and final irrigation was performed with 0.12% chlorhexidine followed by a local anesthetic solution. The canals were obturated with laterally condensed resin-coated gutta-percha (ie, EndoREZ points and EndoREZ

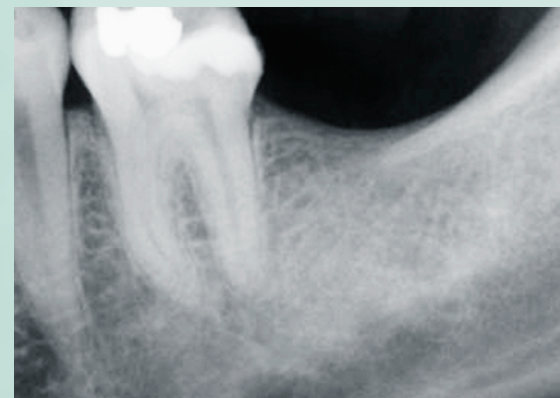

Figure 1. Preoperative radiograph of tooth #19(36) is indicative of a fractured distal marginal ridge with recurrent caries.

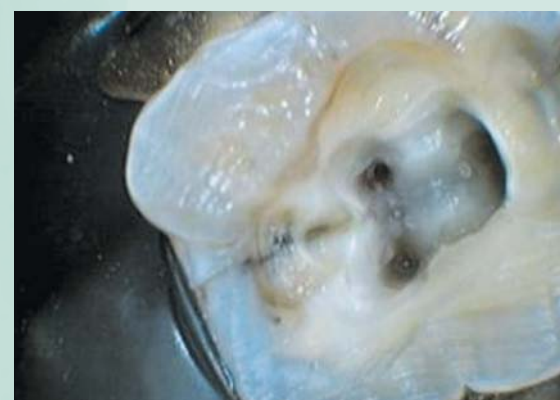

Figure 2. Prominent isthmus between mesiobuccal and mesiolingual canal orifices.

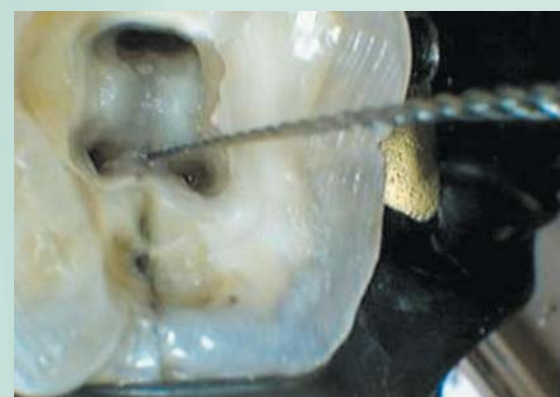

Figure 3. Initial exploration for the middle mesial canal with small-sized hand files.

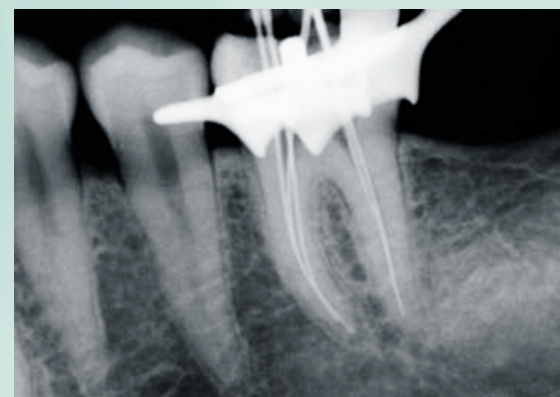

Figure 4. Radiograph with instruments placed at working lengths determined by an apex locator.

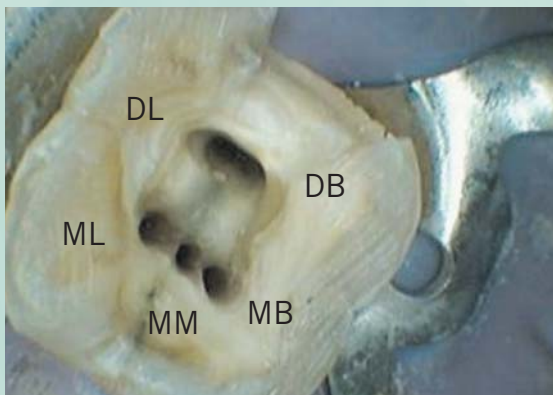


Figure 5. Clinical photograph with the orientation of the canals.

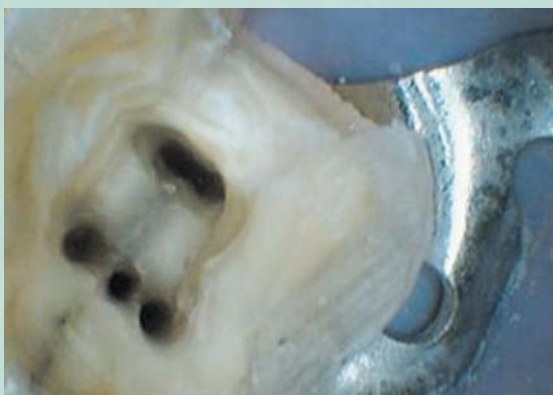

Figure 6. Clinical photograph demonstrating distinctive presence of a separate orifice for the middle mesial canal.

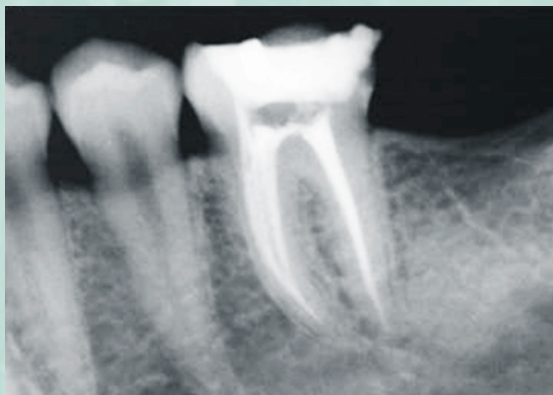

Figure 7. Immediate postoperative radiograph.

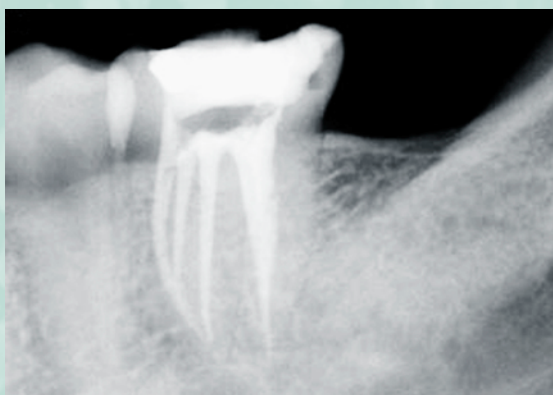

Figure 8. Postoperative radiograph with exaggerated distal angulation demonstrating a confluent mesiobuccal and middle mesial canal and a separate mesiolingual canal.

sealer, Ultradent Products, South Jordan, UT). The orifices were sealed with a light-cured flowable composite (ie, GC UniFil Flow, GC America, IL) and the access was closed with a cotton pellet and an interim restorative material (Figures 7 and 8).

DISCUSSION

In 1981, Pomeranz et al perceived the need to address treatment considerations for the middle mesial canal of mandibular first and second molars. They classified the anatomical variations that exist in these teeth as a **fin**, when an instrument could pass freely between the mesiobuccal or mesiolingual canal and the middle mesial canal. The middle mesial canal was classified as **confluent** when the canal originated as a separate orifice but joined the mesiobuccal or mesiolingual canal in the apical third of the canal. The canal was classified as **independent** if it remained separate from orifice to apex.⁴

Root canal anatomy and morphology has been studied by various investigators and has yielded interesting results. In 1925, Hess published his anatomical study of root canals and concluded that 4% of mandibular first and second molars had four canals, 78% had three canals and 18% had two canals.⁵ In 1971, Skidmore et al reported 28.9% of mandibular first molars had four canals.⁶ Pineda and Kuttler demonstrated that 5.3% of mandibular first molars had four canals.⁷

Not until 1974 did Barker et al report the fifth canal with an independent middle mesial canal in the mandibular first molar; this report was followed by a similar finding by Vertucci and Williams.⁸ Goel et al reported a 15% incidence of three mesial canals in mandibular first molars.⁹ Since then, various case reports of atypical root canal anatomy of the mandibular first molar have been published.¹⁰⁻¹⁵

CONCLUSION

Successful endodontic therapy is based on the foundation of thorough debridement and sterilization of canal systems followed by their complete obturation against future contamination. In the event that root canals are left

Recurring Features of Mandibular First Molars

- 2 roots
 - 1 mesial
 - 1 distal
- At least 3 main canals
- Can also have 4 roots
- Canals can change from 3 to even 6

untreated during endodontic therapy and if the dentist fails to recognize their presence, particularly in teeth with anatomical variations or extra root canals, failure is expected. Magnification, illumination, and familiarity with variations in the canal system will enable dentists to render successful endodontic care. ■

REFERENCES

1. Baugh D, Wallace J. Middle mesial canal of the mandibular first molar: A case report and literature review. *J Endod* 2004;30(3):185-186.
2. Hull TE, Robertson PB, Steiner JC, del Aguila MA. Patterns of endodontic care for a Washington state population. *J Endod* 2003;29(9):553-556.
3. Wayman BE, Patten JA, Dazey SE. Relative frequency of teeth needing endodontic treatment in 3,350 consecutive endodontic patients. *J Endod* 1994;20(8):399-401.
4. Pomeranz H, Eidelman D, Goldberg M. Treatment considerations of the middle mesial canal of mandibular first and second molars. *J Endod* 1981;7(12):565-568.
5. Hess W. *Anatomy of the Root Canals of the Teeth of the Permanent Dentition, Part 1*. New York, NY: William Wood & Company; 1925:35-39.
6. Skidmore AE, Bjorndal AM. Root canal morphology of the human mandibular first molar. *Oral Surg* 1971;32(5):778-784.
7. Pineda F, Kuttler Y. Mesiodistal and buccolingual roentgenographic investigation of 7,275 root canals. *Oral Surg* 1972;33(1):101-110.
8. Vertucci F, Williams R. Root canal anatomy of the mandibular first molar. *J NJ Dent Assoc* 1974;45(3):27-28.
9. Goel NK, Gill KS, Taneja JR. Study of root canal configuration in mandibular first permanent molar. *J Indian Soc Pedod Prev Dent* 1991;8(1):12-14.
10. Mortman RE, Ahn S. Mandibular first molars with three mesial canals. *Gen Dent* 2003;51(6):549-551.
11. Reeh ES. Seven canals in a lower first molar. *J Endod* 1998;24(7):497-499.
12. Fabra-Camos H. Three canals in the mesial root of mandibular first permanent molars: A clinical study. *Int J Endo* 1989;22(1):39-43.
13. Holtzmann L. Root canal treatment of a mandibular first molar with three mesial root canals. *Int Endo J* 1997;30(6):422-423.
14. Ricucci D. Three independent canals in the mesial root of a mandibular first molar. *Endod Dent Traum* 1997;13(1):47-49.
15. Jacobsen E, Dick K, Bodell R. Mandibular first molars with multiple mesial canals. *J Endod* 1994;20(12):610-613.

* Private practice, Apple Valley, California; Clinical Instructor at University of Southern California. Dr. Patel can be reached at rajivpateldds@yahoo.com.